

Retrospective Analysis of Photoaging and Melasma Treatment Using Long-pulsed 532-nm KTP Laser

Sham Shik Shin¹ & Sung Jin Kim²

¹ Clear-skin and Laser Clinic, Gwangju, South Korea

² Chonnam National University Hospital, Gwangju, South Korea

Overview

Melasma is a common pigmentation disorder. It can be especially problematic for those with darker skin, although it can affect any skin type. Melasma is more prevalent in women than in men, and has been reported to impact up to 30% of Southeastern Asian women, accounting for up to 4% of dermatology office visits. Various treatments have been proposed in the literature, but treatment efficacy and safety vary.¹⁻²⁵

Frequency doubled long-pulsed (LP) 532 nm neodymium-doped yttrium aluminum garnet (Nd:YAG) lasers have been used for vascular and pigmentation disorders for more than a decade. However, a limited number of studies have evaluated the efficacy of LP 532 nm lasers for treating photoaging and melasma.

Clinicians continue to research and debate the best treatment modality and regimen for melasma. The primary goal is to optimize clinical cosmetic outcomes with the fewest side effects.

We evaluated the level of overall clinical improvement of melasma symptoms following treatments with a LP 532 nm Nd:YAG laser, and assessed the safety of this laser therapy on Asian melasma subjects.

Background

Melasma is identified by a discoloration on the cheeks, forehead, nose and/or upper lip—areas of the face that have been subject to UV exposure. It is identifiable by a uniform brown color and a well-demarcated, symmetrical hyper-pigmented butterfly shape on both sides of the face. Melasma is caused by an increase of melanin in the dermis, epidermis or both.¹⁻²¹

While the exact cause of melasma remains unknown, a number of contributing factors have been identified:¹⁻²¹

- Female
- Darker skin (Fitzpatrick skin types III, IV, V)
- UV exposure (common in tropical climates)
- Hormones associated with pregnancy
- Oral contraceptive use
- Hormone replacement therapy (HRT) during menopause
- Increased vascularity²²
- Skin irritation
- High stress levels

No treatment regime for melasma has been shown to cure the condition.

Treatments for melasma only provide a temporary benefit for patients with mild, primarily epidermal melasma, and often are associated with side effects and inconsistent or unsatisfactory results.^{1-20, 27} Various

topical creams for controlling melasma have been used—including bleaching agents such as hydroquinone (HQ)—as well as oral agents such as tranexamic acid, with rigorous use of sunscreens. HQ, the most widely used topical bleaching agent, has limited efficacy on mild to moderate melasma.⁸⁻²¹

In addition to topical creams, light and laser devices such as Intense Pulsed Light (IPL), non-ablative and ablative fractional lasers, and low energy Q-switched (QS) 1064 nm Nd:YAG lasers have become increasingly common for melasma treatment.^{6, 7, 23, 24, 25} Low power “laser toning” treatments with 1064 nm QS Nd:YAG have been shown to reduce the brown pigment element of melasma with a series of non-ablative weekly treatments¹⁻⁷ and is gaining popularity, especially in Asia.

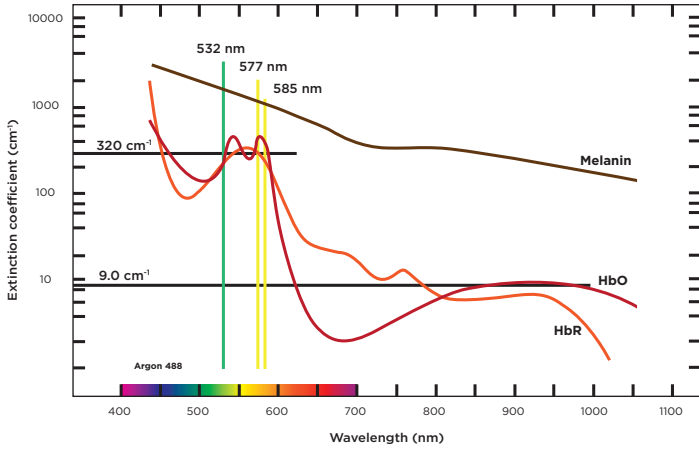
While the QS Nd:YAG treatment methodology is attractive to physicians due to high efficacy, shorter downtime and low risk of complications, it presents the challenge of knowing when to discontinue the treatments. There is a high recurrence of melasma after the QS Nd:YAG procedures have been stopped.^{3, 4, 7, 23, 24, 25}

Researchers have demonstrated that there is a correlation between the number of blood vessels and the pigmentation of melasma.²³ The 532 nm Nd:YAG specifically targets the red pigment of hemoglobin, so

addressing the vascular component of melasma with LP 532nm may improve clinical outcomes. By reducing underlying vascularity, LP 532nm can improve cosmetic appearance and may reduce severity of melasma recurrence.

Figure 1. Absorption Spectrum

This graph shows laser wavelengths and relative absorption by three different chromophores. The 532nm wavelength effectively targets hemoglobin in blood vessels and is also well absorbed by melanin.



Methods

Twenty melasma patients, 18 females and two males, with skin types IV and V were treated with the excel V™ dual wavelength (532/1064) laser from Cutera and were included in this retrospective analysis. Patients ranged in age from 34-64 with an average age of 45. Patients were treated using the 532 nm wavelength only, and received three laser treatments spaced four weeks apart.

Laser Device

The excel V™ high performance, dual wavelength (532/1064) Nd:YAG laser has three operating modes: Long pulse 532 nm for superficial vascular lesions and benign pigmented lesions; LP 1064 nm to target deeper vascular conditions and deeper dermal benign pigmented lesions; and micro-second 1064 nm for skin revitalization, diffuse redness and scars.

Treatment Protocol

In our treatments, 500 shots were delivered in two to three passes. The initial Phase 1 pass was followed by a second phase, and in some cases a third pass was added. A total of two to three passes to deliver 1,000 to 1,500 shots was the prescribed treatment regimen. (Figure 2)

	Phase 1	Phase 2
Wavelength	532 nm	532 nm
Spot	10 mm	10 mm
Duration	10 ms - 15 ms*	15 ms - 20 ms
Laser energy	5.4 J - 6.6 J	5.4 J - 7.0 J

Assessment of Efficacy

Three physicians independently assessed pairs of baseline and post-treatment patient photographs for level of clinical improvement in melasma lesion and erythema. (Figure 3–6 below) Each reviewer assigned a post-treatment improvement score from 0 to 3 for each pair of photographs.

- 0 = 'no improvement'
- 1 = 'mild improvement'
- 2 = 'moderate improvement'
- 3 = 'significant improvement'

These assessments were then calculated to generate a post-treatment improvement score.

Figure 3. Patient 2.

40-year-old with melasma. All reviewers rated post-treatment photograph as '2 = moderate improvement'. There is visible improvement in pigmentation and erythema. Treatment parameters used for this patient: 10 mm spot size, 1,000 total shots; 1st phase: 5.6 J/cm², 10 ms; 2nd phase: 5.6 J/cm², 15 ms

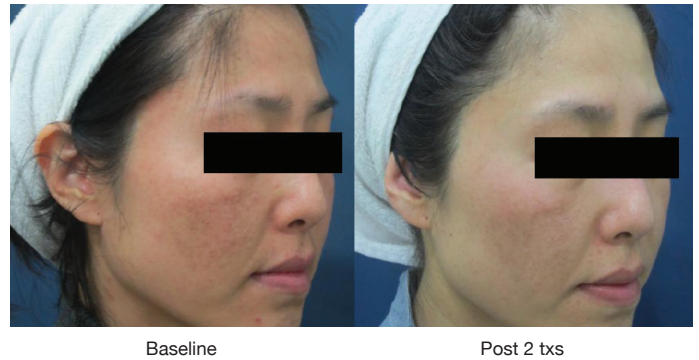


Figure 4. Patient 18.

52-year-old, darker skin type and difficult to treat melasma. Reviewers rated post-treatment improvement on average as '2 = moderate improvement.' There is visible improvement in pigmentation and erythema. Treatment parameters used for this patient: 10 mm spot size, 1,200 total shots; 1st phase: 5.6 J/cm², 10 ms; 2nd phase: 5.6 J/cm², 15 ms

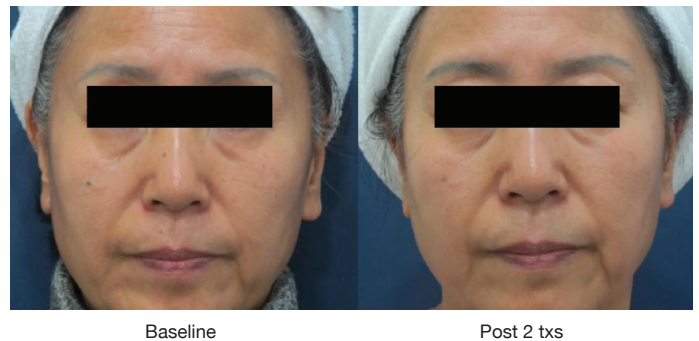


Figure 5. Patient 1.

38-year-old with melasma. Reviewers rated post-treatment improvement on average as '2 = moderate improvement.' There is visible improvement in pigmented areas, erythema and skin texture. Treatment parameters used for this patient: 10 mm spot size, 1,200 total shots; 1st phase: 5.8 J/cm², 10 ms; 2nd phase: 5.6 J/cm², 15 ms

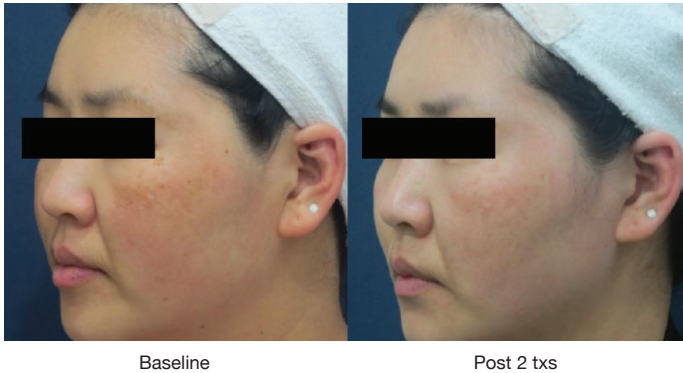
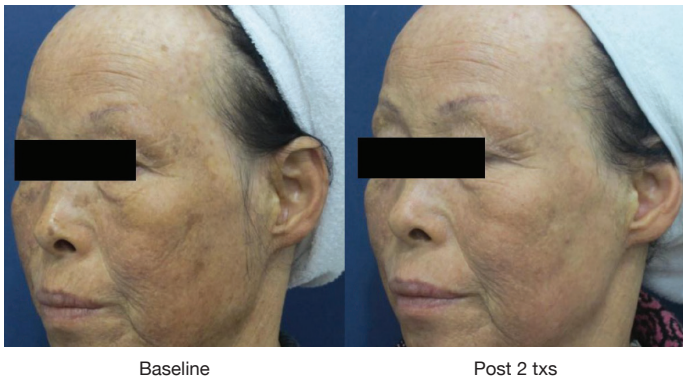


Figure 6. Patient 17.

64-year-old with extensive photoaging and melasma. All reviewers rated post-treatment photograph as '3 = significant improvement.' There is visible improvement in pigmented areas, erythema and skin texture. Treatment parameters used for this patient: 10 mm spot size, 1,200 total shots; 1st phase: 5.6 J/cm², 15 ms; 2nd phase: 5.4 J/cm², 20 ms

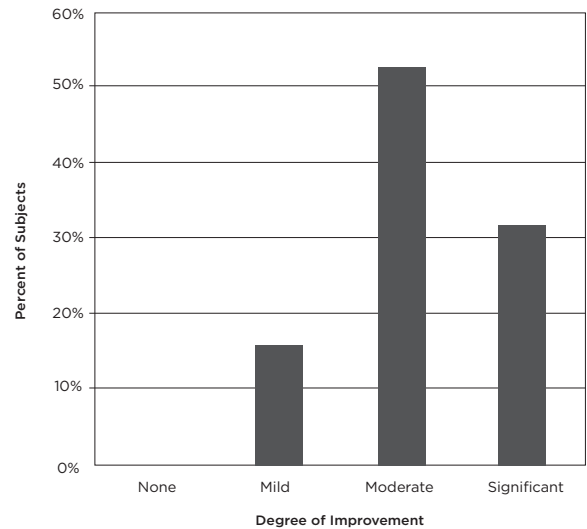


Results

All patients experienced mild to moderate erythema and edema following laser treatment, which resolved within 48 hours.

Based on the independent assessments, all patients showed improvement after laser therapy. More than 8 in 10 patients showed improvement after laser therapy. More than 8 in 10 patients—85%—were rated as having moderate or significant improvement after treatment with the excel V laser. (Figure 7)

Figure 7. Post-treatment improvement



All patients showed post-treatment improvement, with 85% exhibiting moderate to significant improvement.

The difference between mean improvement scores was calculated for each possible combination of reviewer pairs. In addition, the difference between each reviewer and the group mean was calculated. Student's paired t-test was used to test the difference for significance in post-treatment improvement scores (one-sided test, alpha=0.05).

Table 1. Post-treatment Improvement Scores

Reviewer 3 assigned the highest improvement scores, yet all reviewers reported a mean of 2.2 (± 0.64), indicating 'moderate improvement.'

	Mean (± SD)
All Reviewers	2.2 (± 0.64)
Reviewer 1	2.1 (± 0.74)
Reviewer 2	2.1 (± 0.74)
Reviewer 3	2.4 (± 0.68)

Reviewer 3 assigned higher mean improvement scores than the other 2 reviewers and the overall mean for the group. (Table 1) There is a statistically significant difference between the scores of Reviewer 3 and the other reviewers, and the scores of the group as a whole.

In our clinical experience, we recommend the excel V laser for the treatment of melasma combined with small vessels in skin types III and IV. It has less thermal damage compared to other high-energy laser treatments, and thus potentially limits melasma recurrence.

The excel V laser is an effective treatment for addressing the increased melanocyte activity found in refractory melasma skin types, particularly in ethnic (in this case, Korean) skin types.

Discussion

It has been theorized that some cases of melasma can be caused by thermal damage. Melasma symptoms can be aggravated after high-energy laser treatment, sunburn or complications from chemical peels. Other possible causes of melasma include increased quantity of blood vessels or dilated vessels, and increased melanocyte activity, which is thought to contribute to refractory melasma in non-Caucasian or ethnic skin types. As seen in Fig. 8 below, QS Nd:YAG and LP 532 nm KTP lasers had the lowest surface temperatures as measured by an infrared thermometer, suggesting that these are the least likely methods to induce thermal damage.

Figure 8. Infrared Thermometer Measurements (Celsius)

Skin surface temperature difference using infrared thermometer

Laser	Pre-tx	Immediate	Difference
QS Nd:YAG toning (air cooling)	25 (ice roller)	28	3
Long-pulse KTP excel V (contact gel)	28 (ice gel)	32	4
Long-pulse Alexandrite (DCD cooling)	30	36	6
IPL (contact gel)	27.5 (ice gel)	33.5	6
Long-pulsed Nd:YAG (genesis) (no cooling)	30	41	11
Fractora (RF) (no cooling)	30	37.5	7.5
Fraxel Xena (air cooling)	30	35	5

Kim et al reported in 2007²⁹ that vascular endothelial growth factor (VEGF) is significantly increased in the melasma area and may increase melanocyte activity.

In a study published by Lee et al in 2010²³ the researchers tested the efficacy of the copper bromide plus/yellow laser on the skin of Korean women. The results showed a dramatic decrease in the Melasma Area Severity Index (MASI) score. The study concluded that the potential application of an anti-angiogenic laser for the treatment of melasma, specially accompanied by pronounced telangiectasia, is a possible treatment option.

The excel V laser has a longer pulse width, making it more effective in treating melasma by targeting hemoglobin in blood vessels. Contact skin cooling further limits heating from melanin absorption. Our experience reveals that excel V used to treat melasma results in significant improvement. excel V has become a standard of care in our practice to treat melasma with high patient satisfaction.

References

- Salem A, Gamil H, Ramadan A, Harras M, Amer A. Melasma: treatment evaluation. *J Cosmet Laser Ther.* 2009 Sep;11(3):146-50.
- Azzam OA, Leheta TM, Nagui NA, Shaarawy E, Hay RM, Hilal RF. Different therapeutic modalities for treatment of melasma. *J Cosmet Dermatol.* 2009 Dec;8(4):275-81.
- Polnikorn N. Treatment of refractory dermal melasma with the MedLite C6 Q-switched Nd:YAG laser: two case reports. *J Cosmet Laser Ther.* 2008 Sep;10(3):167-73.
- Cho SB, Kim JS, Kim MJ. Melasma treatment in Korean women using a 1064-nm Q-switched Nd:YAG laser with low pulse energy. *Clin Exp Dermatol.* 2009 Dec;34(8):e847-50. Epub 2009 Oct 10.
- Trelles MA, Velez M, Gold MH. The treatment of melasma with topical creams alone, CO2 fractional ablative resurfacing alone, or a combination of the two: a comparative study. *J Drugs Dermatol.* 2010 Apr;9(4):315-322.
- Jeong SY, Shin JB, Yeo UC, Kim WS, Kim IH. Low-Fluence Q-Switched Neodymium-Doped Yttrium Aluminum Garnet Laser for Melasma with Pre- or Post-Treatment Triple Combination Cream. *Dermatol Surg.* 2010;36:909-918.
- Wattanakrai P, Mornchan R, Eimpunth S. Low-fluence Q-switched neodymium-doped yttrium aluminum garnet (1,064 nm) laser for the treatment of facial melasma in Asians. *Dermatol Surg.* 2010;36(1):76-87.
- Grimes PE, Bhawan J, Guevara IL, Colón LE, Johnson LA, Gottschalk RW, Pandya AG. Continuous therapy followed by a maintenance therapy regimen with a triple combination cream for melasma. *J Am Acad Dermatol.* 2010 Jun;62(6):962-7. Epub 2010 Apr 15.
- Grimes PE. An efficacy study of 3 commercially available hydroquinone 4% treatments for melasma. *Cutis.* 2007 Dec;80(6):497-502.
- Torok H, Taylor S, Baumann L, Jones T, Wieder J, Lowe N, Jarret M, Rich P, Pariser D, Tschen E, Martin D, Menter A, Weiss J. A large 12-month extension study of an 8-week trial to evaluate the safety and efficacy of triple combination (TC) cream in melasma patients previously treated with TC cream or one of its dyads. *J Drugs Dermatol.* 2005 Sep-Oct;4(5):592-7.
- Tirado-Sánchez A, Santamaría-Román A, Ponce-Olivera RM. Efficacy of dioic acid compared with hydroquinone in the treatment of melasma. *Int J Dermatol.* 2009 Aug;48(8):893-5.
- Torok HM. A comprehensive review of the long-term and short-term treatment of melasma with a triple combination cream. *Am J Clin Dermatol.* 2006;7(4):223-30.
- Torok HM, Jones T, Rich P, Smith S, Tschen E. Hydroquinone 4%, tretinoin 0.05%, fluocinolone acetonide 0.01%: a safe and efficacious 12-month treatment for melasma. *Cutis.* 2005 Jan;75(1):57-62.
- Chan R, Park KC, Lee MH, Lee ES, Chang SE, Leow YH, Tay YK, Legarda-Montinola F, Tsai RY, Tsai TH, Shek S, Kerrouche N, Thomas G, Verallo-Rowell V. A randomized controlled trial of the efficacy and safety of a fixed triple combination (fluocinolone acetonide 0.01%, hydroquinone 4%, tretinoin 0.05%) compared with hydroquinone 4% cream in Asian patients with moderate to severe melasma. *Br J Dermatol.* 2008 Sep;159(3):697-703. Epub 2008 Jul 4.
- Balkrishnan R, Kelly AP, McMichael A, Torok H. Improved quality of life with effective treatment of facial melasma: the pigment trial. *J Drugs Dermatol.* 2004 Jul-Aug;3(4):377-81.
- Bandyopadhyay D. Topical treatment of melasma. *Indian J Dermatol.* 2009;54(4):303-9.
- Guevara IL, Werlinger KD, Pandya AG. Tolerability and efficacy of a novel formulation in the treatment of melasma. *J Drugs Dermatol.* 2010 Mar;9(3):215-8.
- Ferreira Cestari T, Hassun K, Sittart A, de Lourdes Viegas M. A comparison of triple combination cream and hydroquinone 4% cream for the treatment of moderate to severe facial melasma. *J Cosmet Dermatol.* 2007 Mar;6(1):36-9.
- Guevara IL, Pandya AG. Safety and efficacy of 4% hydroquinone combined with 10% glycolic acid, antioxidants, and sunscreen in the treatment of melasma. *Int J Dermatol.* 2003 Dec;42(12):966-72.
- Rajaratnam R, Halpern J, Salim A, Emmett C. Interventions for melasma. *Cochrane Database Syst Rev.* 2010 Jul 7;7:CD003583. Review.
- Bhawan J, Grimes P, Pandya AG, Keady M, Byers HR, Guevara IL, Colón LE, Johnson LA, Gottschalk R. A histological examination for skin atrophy after 6 months of treatment with fluocinolone acetonide 0.01%, hydroquinone 4%, and tretinoin 0.05% cream. *Am J Dermatopathol.* 2009 Dec;31(8):794-8. 18.
- Jimbow K, Obata H, Pathak MA, Fitzpatrick TB. Mechanism of depigmentation by hydroquinone. *J Invest Dermatol.* 1974 Apr;62(4):436-49.
- Lee HI, Lim YY, Kim BJ, Kim MN, Min HJ, Hwang JH, Song KY. Clinicopathologic efficacy of copper bromide plus/yellow laser (578 nm with 511 nm) for treatment of melasma in Asian patients. *Dermatol Surg.* 2010 Jun;36(6):885-93. Epub 2010 May 7.
- Vachiramon V, Sirithanabadeekul P, Sahawatwong S. Low-fluence Q-switched Nd: YAG 1064-nm laser and intense pulsed light for the treatment of melasma. *J Eur Acad Dermatol Venereol.* 2014 Nov 20. [Epub ahead of print.]
- Zhou X, Gold MH, Lu Z, Li Y. Efficacy and safety of Q-switched 1,064-nm neodymium-doped yttrium aluminum garnet laser treatment of melasma. *Dermatol Surg.* 2011 Jul;37(7):962-70.
- Eudy SF, Baker GF. Dermatopathology for the obstetrician. *Clin Obstet Gynecol.* 1990 Dec 33(4):728-37.
- Wong RC, Ellis CN. Physiologic skin changes in pregnancy. *J Am Acad Dermatol.* 1984 10:929-940.
- Grekin RC, Shelton RM, Geisse JK, Fieden I. 51-nm pigmented lesion laser. Its characteristics and clinical uses. *J Dermatol Surg Oncol.* 1993 Apr; 19(4):380-7.
- Kim EH, Kim YC, Lee ES, Hang HY. The vascular characteristics of melasma. *J Dermatol Sci.* 2007 May;46(2):111-6. Epub 2007 Mar